

A LARGE CARIES LESION

PBL PROBLEM5

DD41

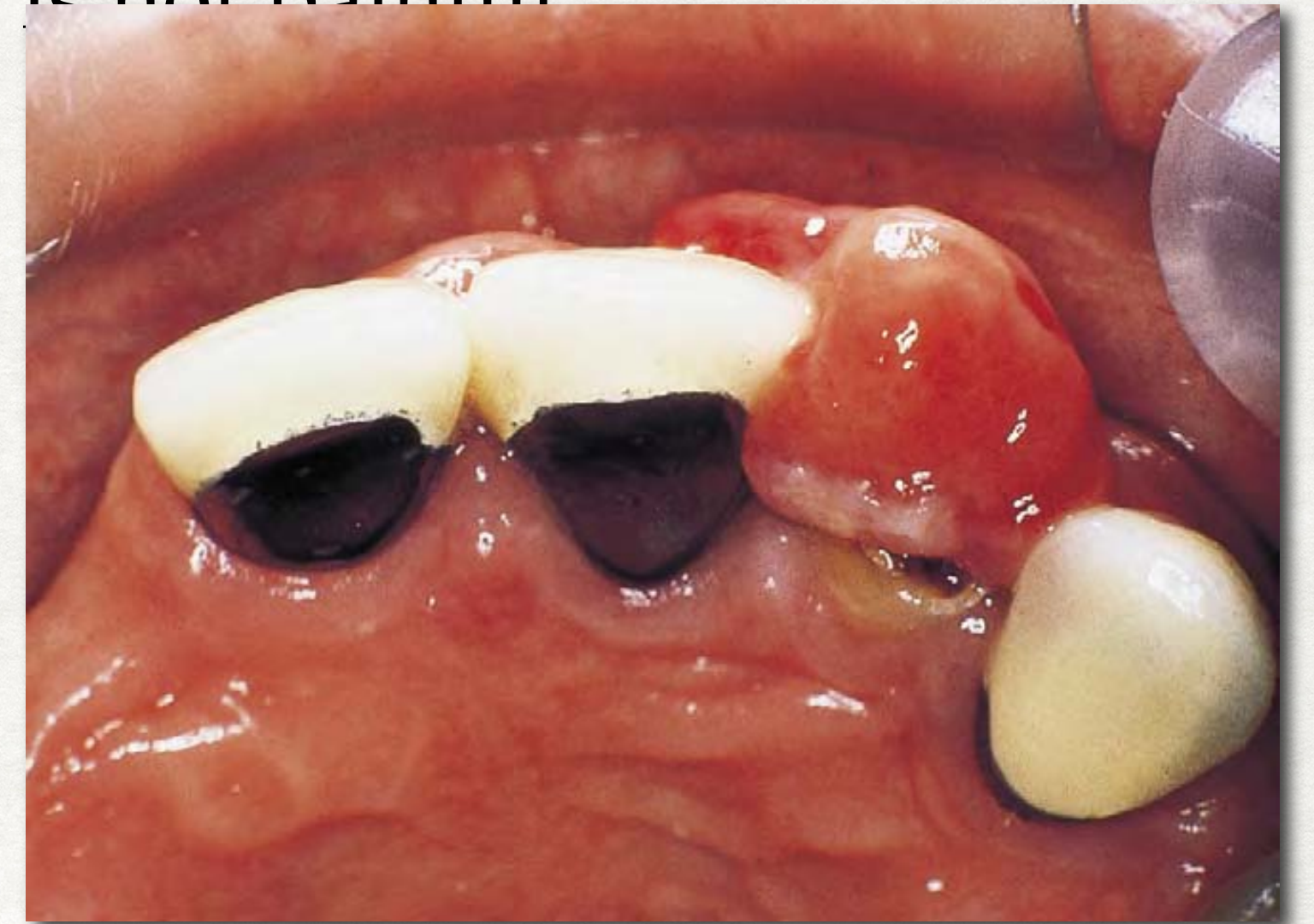
DR. SAO SOKSAN, DR. CHRAY MENGKHENG

CASE HISTORY

A 50 years old man come to UP dental clinic complain with gingival swelling on root #22 .

The patient complains of a lump on the gum at the front of his mouth on the left side. It sometimes bleeds, usually after brushing or eating hard food but it is not painful

Swelling has been present for 4 month ago and it has grow slowly.



Medical history

The patient gives no history of other mucosal or skin lesions.

The patient has hypertension and slightly over weight , but he a well control patient he take atenolol 50 mg daily.

Intraoral examination

- He has partially dentate and relatively few and extensively restored teeth.
- He wears an upper partial denture.
- The root of the upper lateral incisor is present and its carious surface lies at the level of the alveolar ridge.
- The size of lesion 10mm X 7mm
- The teeth on each side of the lesion are restored with metal– ceramic crowns.
- There is a mild degree of marginal gingivitis.
- Most of the interdental papillae are rounded and marginal inflammation is present around crowns and subgingival calculus are visible.

YOUR TASK

What are the learning issues in this case?

What do you know? What don't you know?

What other special tests would you recommend?

What abnormalities can you see on the pictures and x-ray?

What is the problem (including diagnoses)?

What is the etiology of the main diagnosis?

How would you manage this patient? What are the risks? How does his MH affect his management?

(provide at least 4 references)